



Case Report: CASE REPORT OF FACET ARTHROPATHY INDUCED NERVE ROOT COMPRESSION RESULTING IN MOTOR WEAKNESS AND PAIN

submitted by
James M. Cox, DC, DACBR
Diplomate, American Chiropractic Board of Radiology
Developer of Cox® Technic
Fort Wayne, IN

This 79 year old retired white female is seen for the chief complain of neck pain radiating into the left arm with inability to flex the elbow and a generalized weak feeling in the left arm.

History shows that in 1991 she fell on her left side and the injury caused paresis of the left diaphragm. For the present complaints, she stated that they started one month prior to seeing us following turning her head and feeling pain go down her left arm. Three weeks later she could not lift her left arm. She rates the pain in the neck and arm at a VAS score of 7. She states the pain is constant. The only thing that relieves it is medication. She had seen a physician who ordered a CT scan of her neck and told her that the only thing she could do was to take pain pills.

Examination revealed blood pressure 160/80, heart rate of 75 beats per minute of sinus rhythm. She is alert x3, a pleasant women and in apparent good health for her age.

Cervical spine examination reveals ranges of motion 10 degrees flexion, 5 degrees extension, and 50 degrees of bilateral rotation. Marked pain is present to palpation at the left C4-C6 levels. Sensory examination of the upper extremity is normal. Ranges of motion of the left shoulder are very limited with zero degrees of adduction and abduction. The internal and external rotation was 10 degrees. Flexion was zero movement. All motions of the cervical spine were grade 4 or 5 due to the pain. The deep tendon reflexes bilaterally, of the upper extremity, were 2/5 except the left biceps was 3/5. Cervical compression was negative. No carpal tunnel tests were positive. Muscle strength examination of the upper extremities revealed deltoid strength could not be tested due to pain. The biceps strength was 0/5. The triceps strength was 5 and wrist extension and flexion were 4/5. Vertebral artery screens were negative. Let it be noted that there is combined pain and loss of shoulder movement from both the cervical spine

stenosis and rotator cuff disease. Our task is differentiating, to the best of clinical ability, the contribution of each to the clinical presentation.

A note in this case is that prior to seeing us she had visited a chiropractor who used the pro-adjuster several times without benefit and finally decided to send her for x-rays. She was referred to a physiatrist who told her to take pain pills. This patient has also had coronary bypass surgery in 2008.

DIAGNOSTIC IMAGING

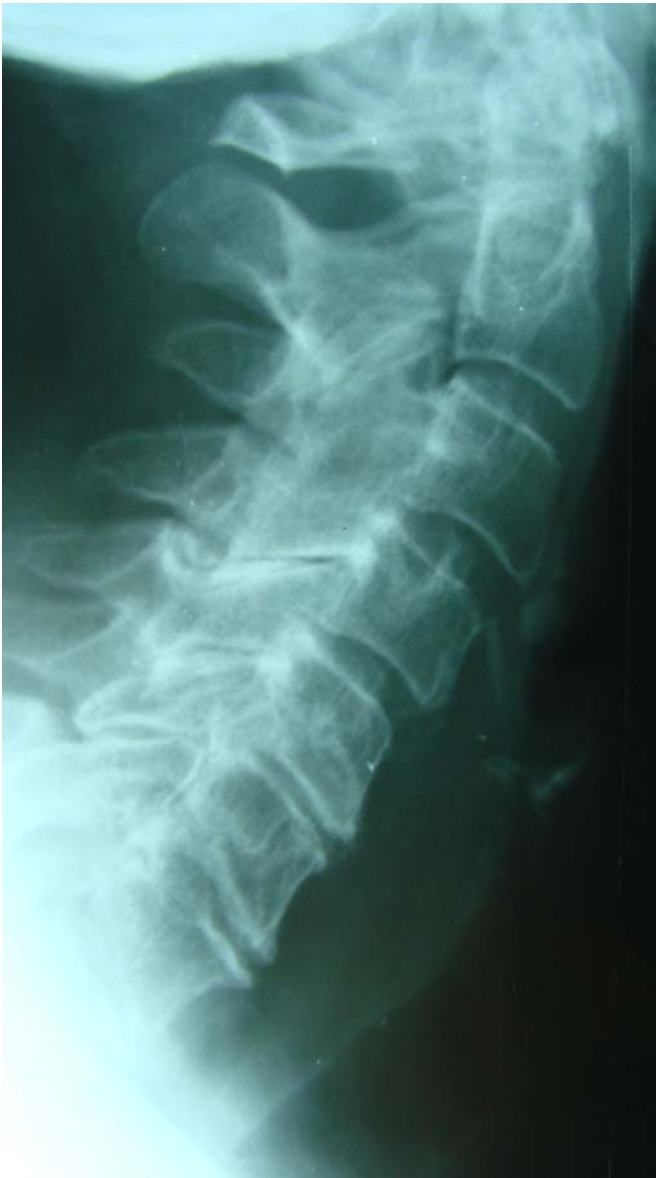

Figure 1. Note the degenerative disc changes of the C5-7 levels and the anterior head carriage

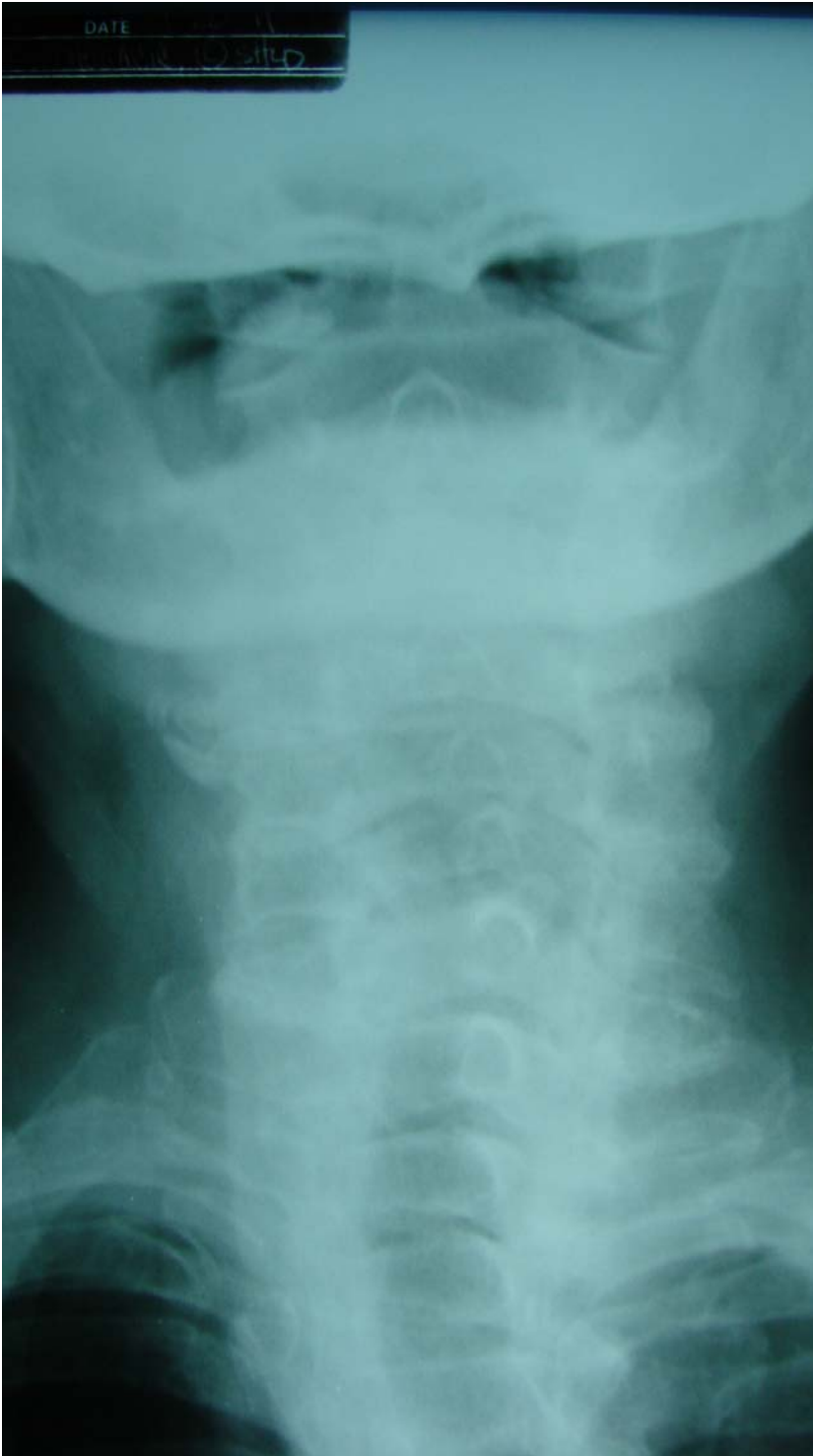

Figure 2. Note the upper thoracic levoscoliosis and dextroscoliosis of the cervical spine

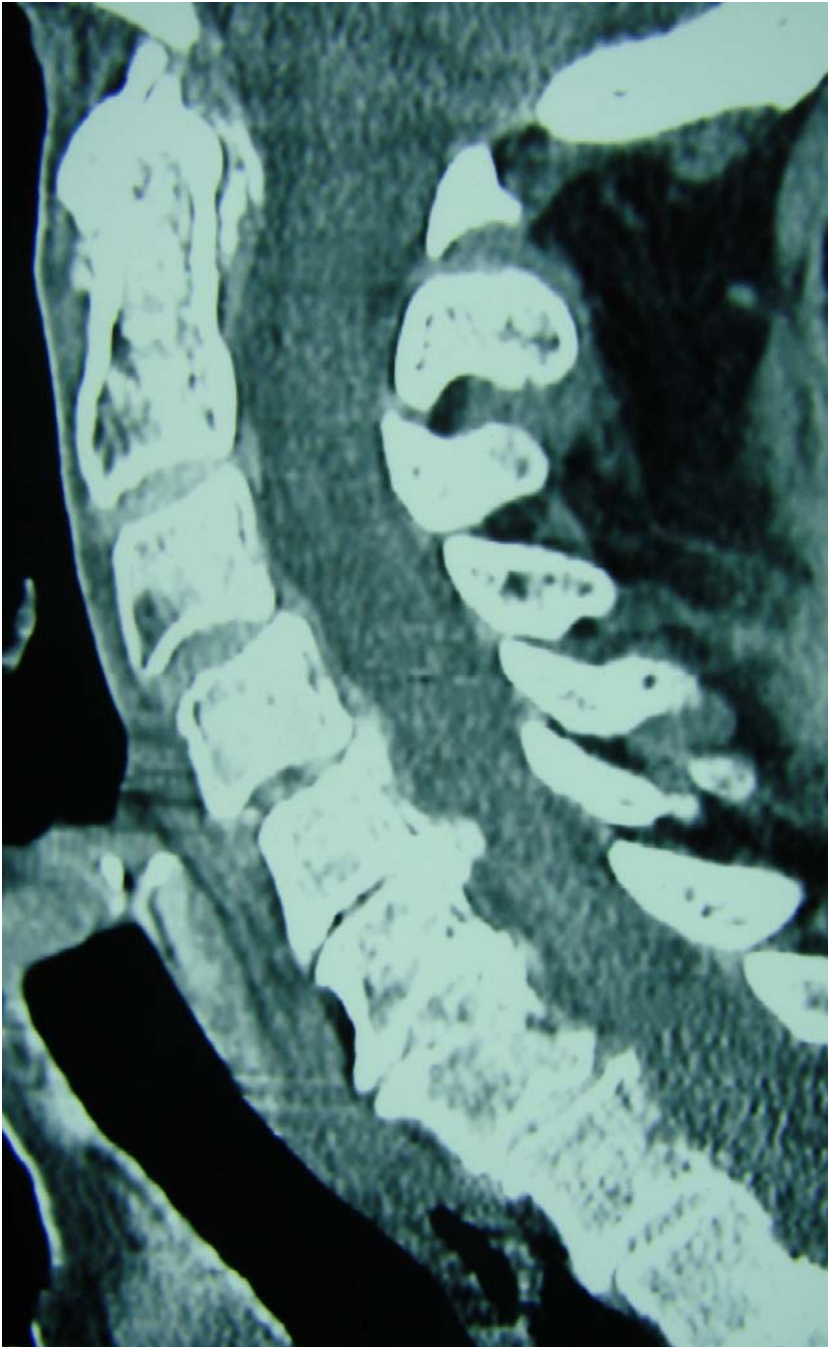


Figure 3. Note the degenerative disc changes from C4 through T1 with the C5-6 posterior endplate hypertrophy into the vertebral canal producing sagittal vertebral canal stenosis. There is almost total loss of the C5-7 disc spaces. Also note the anterolisthesis of C3 on C4 suggesting instability of this motion segment. The C4-5 disc space also shows marked posterior endplate hypertrophy of the posterior superior endplate of C5.

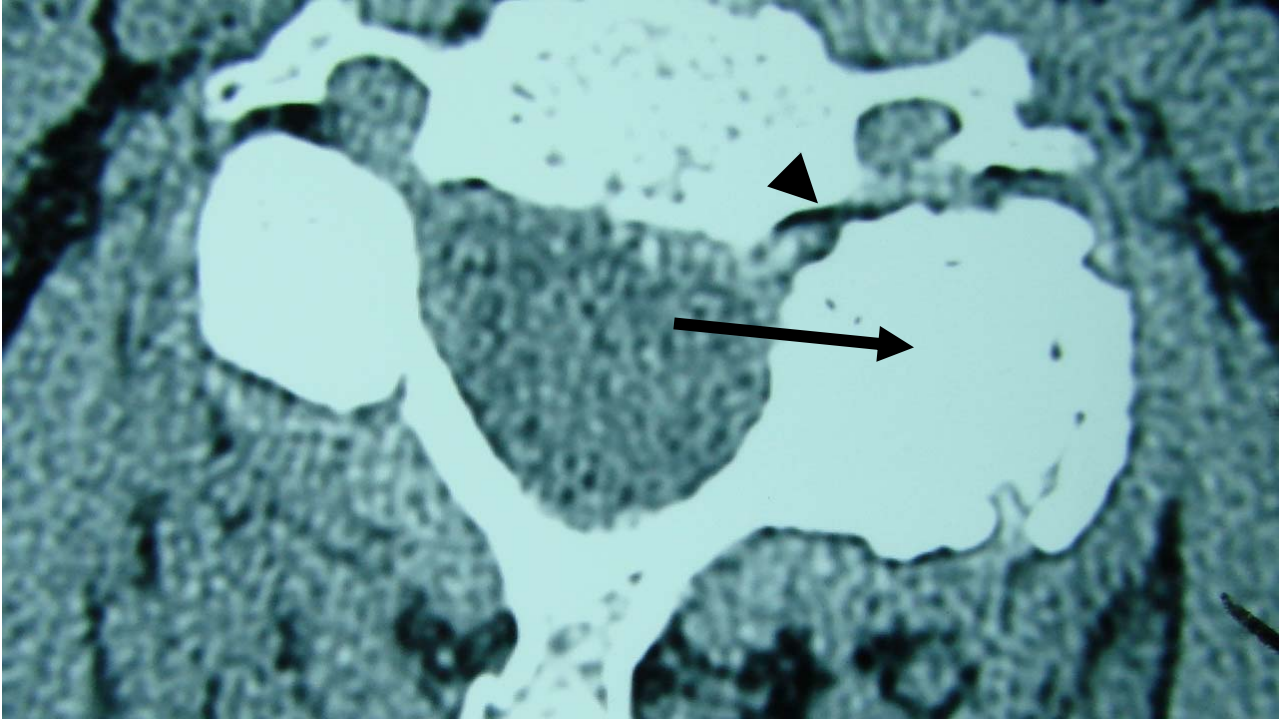


Figure 4. Compare the right and left sided facet joint structures and appreciate the hypertrophic facet changes on the left side (see long arrow) and the narrowing of the osseoligamentous canal (intervertebral foramen) as shown on the arrowhead. The same changes are seen at both the C5-6 and C6-7 levels on the left side which is the side of pain and motor weakness.

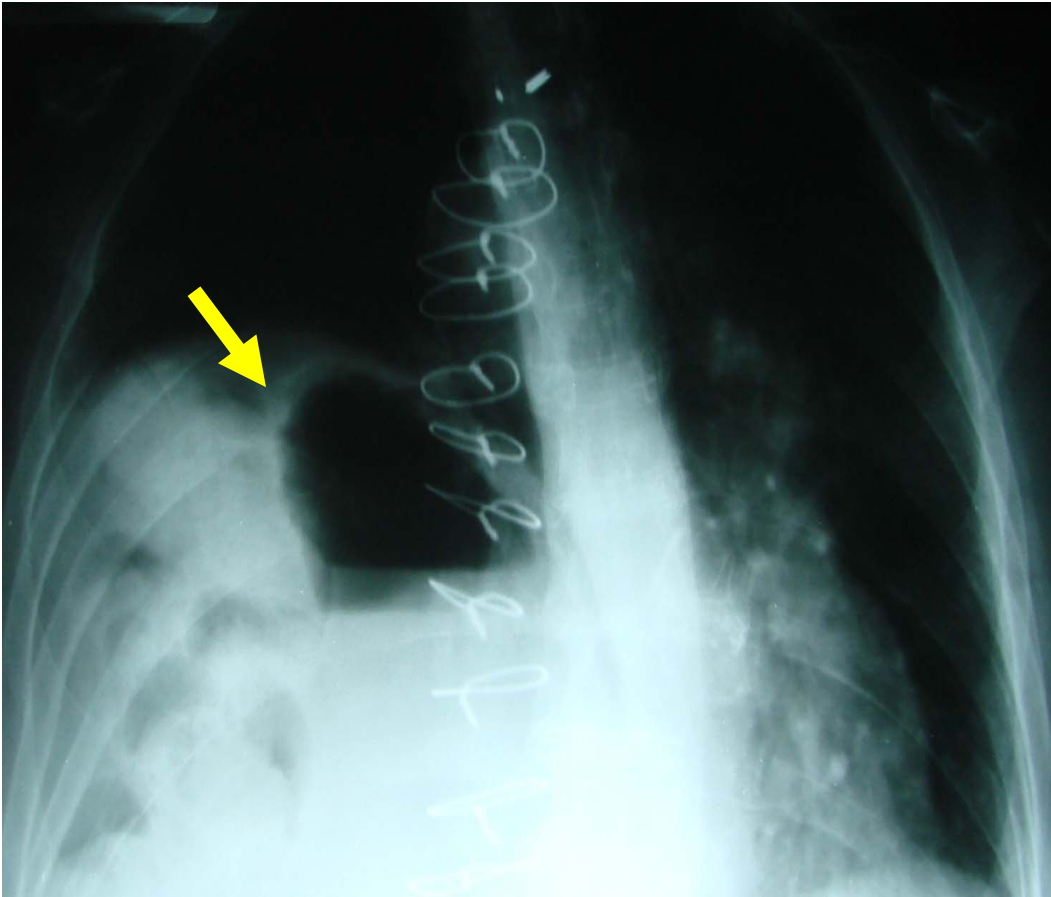


Figure 5. Note the sternal sutures from cardiac bypass surgery and the elevation of the left diaphragm (see arrow) compared to the right side. This is due to paresis of the diaphragm by phrenic nerve trauma many years prior to this episode of left arm pain and weakness. Note the magenblase of the stomach high in the chest. This eventration of the diaphragm makes treatment difficult as this patient cannot lie on her abdomen for long y axis distraction due to dyspnea, so an improvised supine lying technic was used to administer flexion distraction and long y axis distraction.

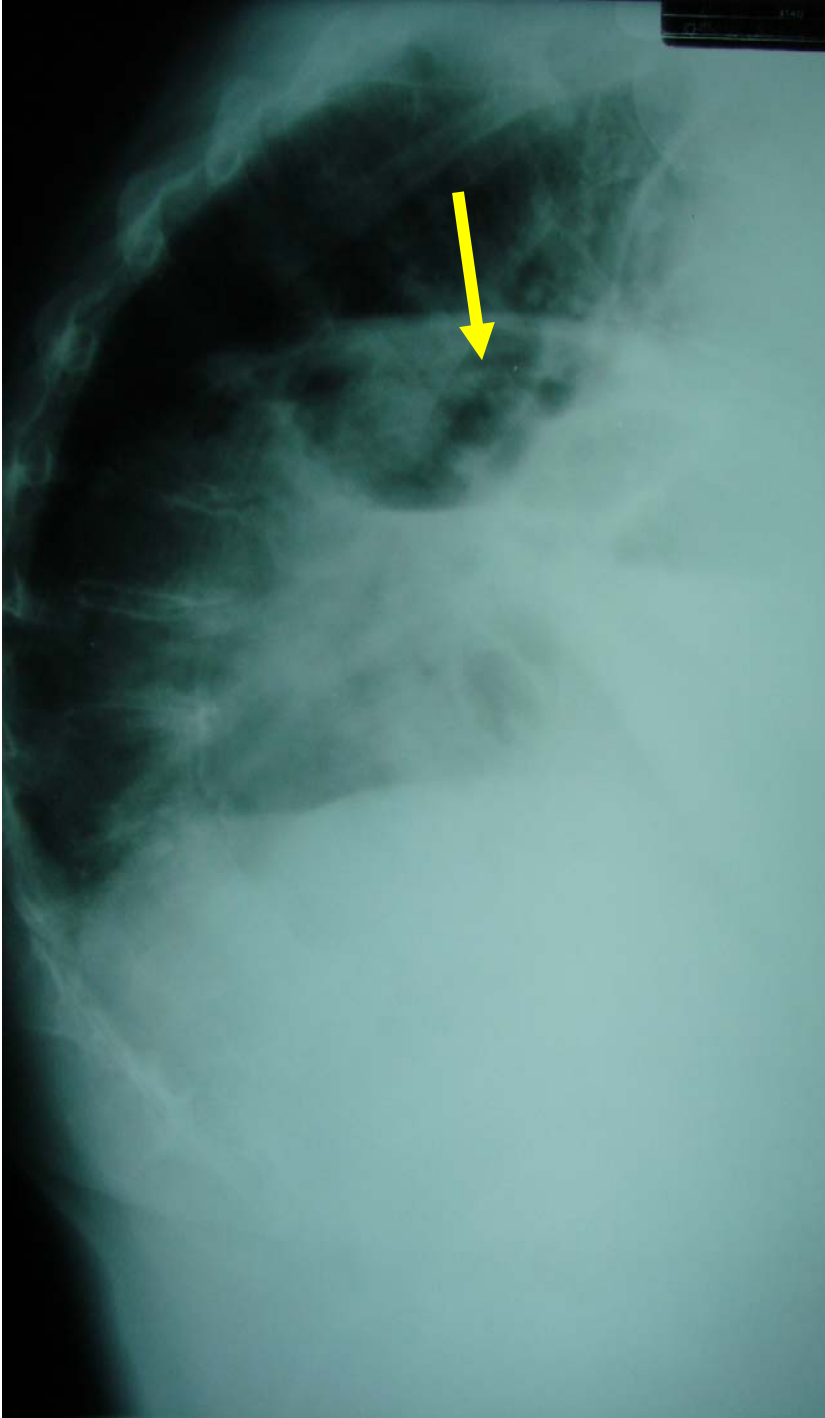


Figure 6. Note the eventrated diaphragm on the lateral projection as shown at the arrow.



INTERPRETATION OF XRAY STUDY:

PATIENT AGE: 79

DATE OF IMAGING: 9/20/11

DATE READ: 9/20/11

IMPRESSION: AP and Lateral thoracic spine x-ray study reveals: (See figures 5 & 6)

1. Evidence of past heart surgery with sternal wires.
2. Eventration of the left diaphragm.
3. Hyperkyphosis with discogenic spondylosis throughout the thoracic spine.
4. Dextroscoliosis of the thoracic and levoscoliosis of the lumbar spine, both greater than 10 degree Cobb angle.
5. Also note that the magenbalse is high within the chest due to the diaphragm eventration.

IMPRESSION: 3 view cervical spine study reveals: (Figures 1-2)

1. Left scoliosis of the cervico-thoracic spine.
2. Anterior head carriage with C5-6, C6-7 degenerative disc disease.
3. Posterior uncinat and facet arthrosis at the C5 and C6 levels.

IMPRESSION: Left shoulder x-ray study reveals. Xrays not shown but report follows.

1. Cystic degeneration of the glenoid fossa and synovial hyperplasia and cystic change of the humeral head. This would indicate degenerative arthritis of the shoulder joint.

IMPRESSION: CT scan performed 9-6-11 reveals: (Figures 3 and 4)

1. Left C5-C6 and C6-C7 facet arthrosis with posterior endplate hypertrophy that does contact the spinal cord at this level. Also noted is anterolisthesis of C3 on C4. The C5-C7 disc also reveals advanced degenerative arthritis and enlarged facet joints due to degenerative arthrosis which creates left sided foraminal stenosis at these levels.

DIAGNOSIS:

1. Left C5-C6 and C6-C7 facet arthrosis creating spinal stenosis of the osseoligamentous canals with compromise of the C5 and C6 nerve roots on the left side.
2. Paresis of the left diaphragm resulting in marked eventration of the diaphragm.
3. Biceps strength on the left side is reduced to 0/5 with grade 4 or 5 strength of wrist flexion and extension.
4. Dynamometer strength on the right side was 50 lbs and on the left was 40 lbs.



TREATMENT:

Long Y axis decompression with the Cox instrument performed 3x weekly with tetanizing rehab current to the left biceps muscle. Active exercise started of the left biceps muscle as pain reduces and response to flexion distraction begins to allow biceps muscle contraction. This occurred on the third visit when this patient started home active flexion exercises of the biceps muscle. The expectations are 50% relief of pain and increase in strength within 4 to 6 weeks of treatment. It is explained to this patient that she may never recover to 100% of her strength but that surgery is not recommended by any of her physicians and this conservative route will give her the greatest opportunity for maximum motor power return.

This patient could not lie on her stomach for long Y axis decompression manipulation so we therefore treated her by lying supine, releasing the long Y axis movement of the head piece and applied the long Y axis decompression from C4-C7 with the patient lying supine.

CLINICAL OUTCOME:

After the first treatment the patient would raise her arm with flexion of the biceps muscle and had no arm pain. At this point she was started on 10 flexion repetitions of biceps exercise at home as well as continuing the treatment in clinic. On her 3rd visit the patient reported she had had two good days without pain and continued return of motor power but that the night before she slept poorly and the pain had increased. The treatment in clinic was repeated, resulting in relief of pain and constant return of motor power with longer intervals of relief and strength.

Interesting note about this patient's left arm pain and her paresis of the left diaphragm. The phrenic nerve is the sole motor supply to the diaphragm and also has sensory fibers. The phrenic nerve arises chiefly from the 4th cervical ramus but also from the 3rd and 5th ramus. It is also interesting that the nerve supply of the biceps muscle is the musculocutaneous nerve, which is the C5 and C6 nerve.

The important points of this case are as follows:

1. The left paresis of the diaphragm creates dyspnea when this patient lies prone, and therefore she must be treated in a supine position. The modification of this technique was described above.
2. Remember that in paresis of the diaphragm the amount of elevation varies; in this case the elevation was extreme.
3. This case represents the need for adaptation of technique depending upon patient needs.